أم دم الشريان المساريقي العلوي:
(مراجعة وحالة مرضية)

عبد الرحمن الأيوبي* **هشام حمزة****

سليمان غانم*** **حسام مخول******

الملخص

تعدُّ أم دم الشريان المساريقي العلوي حالة نادرة، إذْ تمثل فقط 5.5% من كل أمهات دم الشرايين الحشوية. جرت أول محاولة إصلاح جراحية من قبل Stevenson عام 1895، انتهت بوفاة المريض بسبب النزف. قام العالمان DeBakey و Cooley بأول عملية استئصال جراحي ناجحة لأم دم شريان مساريقي علوي.

تعدُّ الأمراض الإنتانية والتصلب العصيدي الأسباب الأكثر شيوعاً لأمهات الدم هذه. يجري التشخيص باستخدام الأمواج فوق الصوتية والتصوير الطبقي المحوسب وتصوير الأوعية. يجري التداخل عليها جراحياً أو بتقنيات عبر الجلد.

نقدم هنا تقرير حالة عن أم دم شريان مساريقي علوي عند مريض عمره 39سنة، راجع بشكاية ألم بطني. أجريت جراحة تضمنت ربط أم الدم وإعادة التروية بوصلة صافن كبير.

في الخاتمة، أم دم الشريان المساريقي العلوي حالة ناردة، ولكنها ذات نسبة اختلاطات مرتفعة، وهذا يحتم علينا المعالجة عند القيام بالتشخيص. يعاني المرضى عادة من ألم بطني معمم، يشخص تشخيصاً خطأ غالباً بحالات أخرى أكثر شيوعاً.

كلمات مفتاحية: أم دم، شريان مساريقي علوي، ألم بطني

* أستاذ- قسم جراحة الأوعية- كلية الطب البشري – جامعة دمشق.

** مشرف- قسم جراحة الأوعية- كلية الطب البشري – جامعة دمشق.

*** مقيم- قسم جراحة الأوعية- كلية الطب البشري – جامعة دمشق.

**** مقيم- قسم جراحة الأوعية- كلية الطب البشري – جامعة دمشق.

Superior Mesenteric Artery Aneurysm: Review and a Case Report

Abdelrahman Alayoubi* **Hamze Hisham****

Ghanem Souleiman*** **Makhoul Hosam******

Abstract

Superior mesenteric artery aneurysm (SMAA) is a rare condition, represents only 5.5% of all splanchnic artery aneurysms. Stevenson attempted the first surgical repair of an SMAA in 1895; this SMAA resulted in death from hemorrhage. In 1949, DeBakey and Cooley performed the first successful resection of a SMAA.

Atherosclerosis and infectious diseases are the most common cause. Ultrasonography, computerized tomography, and arteriography are used to make the diagnosis and treatment is achieved by surgery or percutaneous techniques.

We herein report a SMA aneurysm detected in a 39 years old patient with complaint of abdominal pain. The surgical treatment involved the aneurysm ligation and revascularization with greater saphenous vein interposition graft.

In conclusion, Superior mesenteric artery aneurysm is a rare condition but has high rate of complication. Therefore, once the diagnosis is made it must be treated. Patients usually have general abdominal pain that can often be mistaken for much more common conditions.

Key words: Aneurysm, superior mesenteric artery, abdominal pain

* Consultant at vascular surgery dep, Damascus University.
** Resident at vascular surgery dep, Damascus University.
*** Resident at vascular surgery dep, Damascus University.
**** Chairman of vascular surgery dep, Damascus University.

Case Report:

A 39 years old man presented to emergency department with severe epigastric abdominal pain radiated to the right lumber, this pain occured as attacks of pain for approximately half hour without relating to meals. These symptoms had been presented for the previous 10 days with nausea, vomiting and absence of stool or gas from 3 days. Five months before presentation he had undergone an aortic valve replacement and one month before presentation he had intracranial hemorrhage. He did not use tobacco products last six months. White cell count was 6.7 k/uL and neutrophil granulocytes was 76%. The patient underwent an abdominal and pelvic computed tomography (CT) scan with intravenous contrast, abdominal ultrasound and AXR. There was no evidence of bowel ischemia. Physical examination revealed a tenderness was noted over all the abdomen with palpable mass. Abdominal ultrasound showed "an alternating sonolucent mass and distended bowels with paresis". The patient was taken to the operating room and exploratory laparotomy was preformed because of suspicion of mesenteric ischemia (distended bowels and colons with change in color improved after warming them + appendectomy). After surgery he placed on bowel rest, and anticoagulated with heparin. His symptoms didn't resolved.

Because of suspicion of SMAA at previous CT, his case was studied more by multi slice CT (Abdominal Aorta and viscerals arteries) figure 3, 4. It was an aneurysm like opacity 27x31mm in size at the mid portion of the SMA and it had partial thrombosed lumen. There was no aneurysm or stenosis of other vessels.

Because the need to save superior mesenteric artery branches near the neck of aneurysm surgical treatment performed. SMAA was ligated and replaced with greater saphenous vein interposition graft.

Postoperatively, the patient was successfully extubated and the pain completely disappeared after the surgery. After 2 days, he tolerated a diet without difficulty.

Follow-up ultra sound confirmed good blood flow through the graft and the patient was discharged home six days later.

Histopathologic examination demonstrated that the aneurysmal wall was fibrous wall with granular inflammatory tissues and purulence, There was no finding of specific lesion. As anticipated, cultures of the aneurysm were negative due to preoperative antibiotics.

Two months later, ultra sound revealed a patent SMA bypass with normal flow velocities. The patient had remained asymptomatic. The patient had had non-bleeding diarrhea since the intervention.

Three months later, the patient presented to emergency department with fatigue, cough and fever. Echocardiography revealed "a prosthetic aortic valve working bad with moderate regurgitation, floating vegetations attached to arotic valve ring and abscess around aortic valve ring extended toward left atrium". The diagnosis of infective endocarditis was based upon a constellation of history, clinical findings, and echocardiography.

Discussion

SMAAs represent only 5.5% of all splanchnic artery aneurysms and appear to have an equal gender distribution.[2] The exact prevalence of the SMA aneurysm are not known [8] In one series mean diameter of the VAA was 2.4 cm [9] but it has been reported that it can reach up to 11 cm in diameter [10]. Most commonly found within the first 5 cm of the artery. Most mycotic aneurysms occur in patients less than 50 years of age, whereas nonmycotic aneurysms typically affect patients after the sixth decade of life . [4] In this case the aneurysm diameter was 30mm and it located at the mid portion of the SMA. The patient was 39 years old.

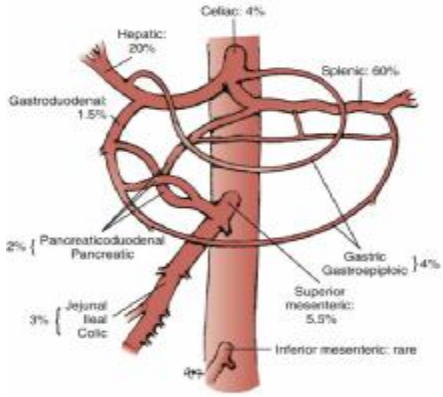

Figure 1: Relative incidence of aneurysms affecting the arteries of the splanchnic circulation as reported in the literature. [2]

Pathogenesis and Risk Factors:

The SMA is the number 1 site of infected aneurysms outside the aorta itself. [4] Mycotic aneurysms account for 60% of cases and are thought to occur most commonly as a result of subacute bacterial endocarditis with infection by nonhemolytic Streptococcus. The predilection for mycotic aneurysms to be manifested in the SMA is incompletely understood but may be related to the

orientation and size of the origin of the SMA as it arises from the aorta; this geometric configuration may predispose to lodging of septic cardiac emboli in this anatomic location [2].

Other causes include local connective tissue disease or atherosclerosis(25%), as well as false aneurysms secondary to pancreatitis, dissection, or trauma (<2%).[2][4]

In our case, although the cultures of the aneurysm were negative , the aneurysm was thought to be mycotic due to the patient's history, the absence of any other vascular disease and the diagnosis of endocarditis after 3 months.

Clinical Findings and Diagnosis:

The majority of SMAAs, 70% to 90%, are symptomatic at initial evaluation. Patients usually have general abdominal pain that can often be mistaken for much more common conditions [2] Some may develop typical intestinal angina with postprandial pain. In many cases it is difficult to determine if the etiology is due to relative mesenteric ischemia or to direct aneurysm expansion. [4] This abdominal pain may become severe if arterial compromise or embolization occurs. Other symptoms involve nausea, vomiting, gastrointestinal hemorrhage and fever [2]. Fever is present in up to 20% of patients. [2] Fever may be a prominent finding in mycotic aneurysms [4].

The patient presented with severe abdominal pain, nausea and vomiting without any fever.

Symptoms	No.	Percent*
Abdominal pain	35	67
Mass	14	27
Fever	10	19
Nausea, vomiting	10	19
Gastrointestinal hemorrhage/ hemobilia	8	15
Jaundice	8	15
Anemia	6	12
Shock	6	12
Asymptomatic	5	10

Figure 2: Percentage of total cases (some cases may have had more than 1 symptom). Summary of 52 reported SMAA cases by Shanley [4]

Investigation:

These modalities provide the best information in regard to location, evidence of rupture, and presence of collateral flow, all of which are vital pieces of information to have before surgical repair[2]. Many SMAAs will reveal rims of calcifications on plain radiographs as demonstrated [2]. Duplex ultrasound imaging has been shown by many to be valuable as a quick and reliable tool for diagnosis[2]. Most SMAAs are currently being diagnosed preoperatively via abdominal computed tomography or angiography [2]. Arteriography is necessary to define the exact location of the aneurysm and its relationship to other SMA branches. [5]

Figure 3: multi slice CT revealed the SMAA and the presence of collateral flow.

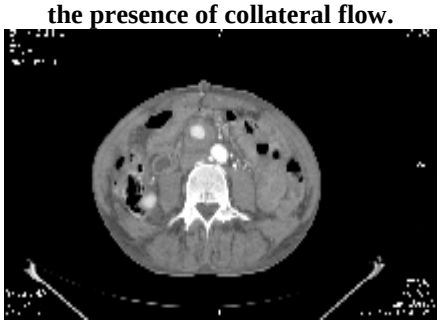

Figure 4: . It was SMAA and it had partial thrombosed lumen.

Complication:

these aneurysms are particularly dangerous because their complications may jeopardize the entire small bowel. These complications include aneurysm rupture, acute thrombosis and distal embolization [2]. Rupture has been noted in 70% of symptomatic patients and is associated with a mortality rate (30% to 90%) that is significantly worse than that in patients undergoing elective repair [5] [2].

Indication:

Treatment of SMAAs should be considered regardless of size or symptomatology because of the high mortality risk associated with potential rupture [2]. Because of the high rate of complications, intervention is recommended for all patients at low surgical risk. [7]

SMA false aneurysms, especially when mycotic, often have some element of contained rupture at the time of diagnosis, and in these cases treatment is certainly warranted [2]. Nonetheless, observation and

conservative management may also be reasonable for small, noninfected SMA true aneurysms without associated symptoms or complications [2].

Treatment:

Treatment must be individualized and based on the etiology, size, risk of rupture and anatomic location of the lesion; co-morbid conditions of the patient; and the potential morbidity of the proposed procedure. [2]

endovascular techniques for the treatment of SMAAs are largely dictated by the anatomic location of the disease. SMA aneurysmectomy may prove hazardous because of the close proximity of neighboring structures, such as the superior mesenteric vein and the pancreas Because these aneurysms typically occur in the very proximal portions of the parent artery, a landing zone for coil embolization or stent-graft seal is often not feasible and open repair may be necessary.[2]

The obvious concern with transcatheter therapy for SMAA is the inability to directly assess bowel viability .[5]

Surgical Treatments:

Transabdominal, transperitoneal exposure is most frequently utilized, but for proximal SMAA a retroperitoneal approach may be preferable. [5]

Surgical options include aneurysm exclusion (ligation), excision, revascularization, or any combination of these therapies [2]

When surgical therapy is considered, some SMAAs can be ligated and excised safely because of the extensive collateral flow to the intestines via the celiac artery and the inferior mesenteric artery. [2] Probably because of the prominent role of infection in these aneurysms, the majority of reports describe ligation or ablation without revascularization. [5] As well as the proximal location of most SMAA, enables this approach, although adjunctive bowel resection may be necessary. [5]

Saccular aneurysms of the SMA, in particular, can be treated by aneurysmorrhaphy. [2]

Temporary occlusion of the SMA with intraoperative assessment of bowel viability offers a means of identifying cases in which mesenteric revascularization is necessary using great saphenous vein or prosthetic conduits. [2] When not contraindicated by extensive sepsis, revascularization with autogenous conduit is probably a preferable approach . [5] Given the relatively young age of the patient concern for a mycotic aneurysm prompted the use of saphenous vein as the conduit. [4] This bypass takes origin from the anterior aorta (aortomesenteric) or intact proximal SMA (interposition) and carried to the normal vessel beyond the aneurysm.

Endovascular Treatments

Severe atherosclerosis of the proximal SMA and splanchnic aorta, as is often present in cases of SMAA, can make revascularization procedures especially challenging. The current era of endovascular therapy has provided an important alternative treatment option for such challenging cases. Embolization techniques using coils, particles, or “glue” have been used successfully. Transcatheter occlusion of saccular aneurysms with discrete necks arising from the side of the SMA occasionally may be justified . [2]

Likewise, aneurysm exclusion with covered stent-grafts has the advantage of preserving the enteric circulation, which may be especially important in cases in which the normally robust collaterals have been compromised as a result of splanchnic occlusive disease or previous bowel resection.[2]

In cases of mycotic aneurysms involving the SMA, some have recommended intravenous antibiotics before endovascular interventions.[2]

Surgical treatment performed in this case to save superior mesenteric artery branches near the neck of aneurysm. We could assess bowel viability intraoperative. Revascularization is necessary because aneurysm location and propagation of thrombus beyond the middle colic and pancreatico-duodenal branches of the superior mesenteric artery resulted in occlusion of collateral flow from the celiac and inferior mesenteric arteries.

SMAA was ligated and replaced with greater saphenous vein interposition graft.

Conclusion

Superior mesenteric artery aneurysm is a rare condition but has high rate of complication. Therefore, once the diagnosis is made it must be treated. Patients usually have general abdominal pain that can often be mistaken for much more common conditions, and thus a high index of suspicion is required for diagnosis.

References

[1] Venyo AK, Bakir E. Enlarging Superior Mesenteric Artery Aneurysm Successfully Treated by Selective Angiography And Embolization With Terumo Hydrocoil: A Case Report And Review Of The Literature. Can be found at: http://www.webmedcentral.com/article_view/1689. Visit time:12-12-2012

[2] Cronenwett JL, Johnston KW. Rutherford's vascular surgery: chapter 138. 2010: 2140-55

[3] DeBakey ME, Cooley DA. Successful resection of mycotic aneurysm of superior mesenteric artery: Case report and review of literature. Am Surg, 1953; 19:202-12

[4] Lorelli DR, Cambria RA, Seabrook GR, Towne JB. Diagnosis and management of aneurysms involving the superior mesenteric artery and its branches-a report of four cases. Vasc Endovascular Surg. 2003 Jan-Feb;37(1):59-66.

[5] Ascher E. Haimovici's Vascular Surgery: chapter 75. 2004: 902-12

[6] Johnson JR, Ledgerwood AM, Lucas CE.. Mycotic aneurysm: New concepts in therapy. Arch Surg. 1983 May;118(5):577-82.

[7] Pasha SF, Gloviczki P. Splanchnic Artery Aneurysms. Mayo Clin Proc. 2007; 82(4): 472-479

[8] Kopatsis A, D'Anna JA, Sithian N, Sabido F. Superior mesenteric artery aneurysm: 45 years later. Am Surg. 1998 Mar;64(3):263-6

[9] Tulsyan N, Kashyap VS, Greenberg RK, Sarac TP, Clair DG, Pierce G, Ouriel K. The endovascular management of visceral artery aneurysms and pseudoaneurysms. J Vasc Surg. 2007 Feb;45(2): 276-83

[10] Ricardo C, Rocha M., Marcio M. Giant superior mesenteric artery aneurysm associated with infrarenal abdominal aortic aneurysm. J Vasc Br. 2003; 2(3):227-9.

تاريخ ورود البحث إلى مجلة جامعة دمشق 2011/12/13.

تاريخ قبوله للنشر 2012/4/1.