

## الموجودات التشريحية المرضية في الصرع الصدغي المزمن المعند دراسة لـ 66 مريض سوري

رائدة الخاني\*

### الملخص

خلفية البحث وهدفه: لايزال الصرع مرضاً صعب الفهم والعلاج. هذا البحث هو دراسة تشريحية مرضية للعينات الجراحية للفص الصدغي المستأصل وللحصين في حالات الصرع الصدغي المعند، لتحديد الآفات المرافقة المسببة أو الناتجة. ففي الأدب الطبي المنشور تنوع كبير في هذه الآفات.

طرائق البحث: أجريت دراسة استباقية تشريحية مرضية لعينات الفص الصدغي والحصين المستأصلين جراحياً من مرضى يعانون من صرع معند في مركز معالجة الصرع في مشفى الاسد الجامعي. هذه الدراسة أجريت خلال فترة حوالي 7 سنوات، بين شهر تشرين الاول 1997 وشهر كانون الأول 2004.

النتائج: بلغ عدد العينات 66 عينة استئصال جراحي من 66 مصاباً بالصرع المعند الذي استمر 1-32 عاماً. تراوحت أعمار المرضى بين 2-45 عاماً (وسطي 22 عاماً) بينهم 33 ذكراً و33 أنثى. بينت الدراسة التشريحية المرضية في كافة الحالات علامات أذية عصبونات مع فقدان للعصبونات، وخلل تنسج قشري دماغي، ودباق صدغي. شوهدت آفات ورمية في 28 حالة، تتضمن: أورام عصبية دبقية في 20 حالة وأورام أو تشوهات وعائية في 5 حالات، وأورام دبقية في 3 حالات (4.5%).

الاستنتاج: وجد في هذا البحث تنوع كبير في الآفات المشاهدة في الصرع المعند، مع وجود علامات ثابتة لأذية عصبونية وفقدان للعصبونات ودباق. وقد وجدت آفات ورمية في 42% من الحالات.

\* أستاذة - قسم التشريح المرضي - كلية الطب - جامعة دمشق.

## **Histopathological Findings in Chronic Pharmacoresistant Temporal Epilepsy: Study of 66 Syrian Patients**

**\*Raydeh Al KHani**

---

### **Abstract**

**Background and Objective:** Epileptic seizures is clinically not yet well predicted and comprehensible. This was a pathological study of surgical specimens of resected temporal lobe and hippocampus in chronic pharmacoresistant temporal epilepsy in order to determine the associating lesions; that might be the cause or the result of this type of epilepsy. Wide a variety of lesions as have been reported in the literature.

**Methods:** This was a prospective histopathological study of successive mesial temporal and hippocampal structures removed from patients suffering from refractory epilepsy, between Oct 1997 and Dec 2004 in the Epilepsy Center of Damascus University.

**Results:** Sixty six consecutive surgical specimens from 66 patients with refractory epilepsy lasting for 1-32 years were received and studied. Our series included 33 males and 33 females (2-45 y; average 22 y). Pathological study revealed, in all cases, signs of neuronal injury with cell loss, cortical dysplasia/ dysgenesis, and gliosis. Tumoral lesions were observed in 28 cases (42%), including neuroglial tumors in 20 cases, vascular tumors/malformations in 5 cases, and gliomas in 3 cases.

**Contusions:** In this series, neuronal injury and loss were found in all cases, associated with gliosis. Tumors and malformations were found in 45.5% of cases.

---

\* Professor, Department of Pathology, Faculty of medicine Damascus University.

## **Introduction**

Epilepsy affects up to 2% of the general population and begins mostly in childhood or adolescence. The etiology of pharmaco-resistant epilepsy is not well understood; genetic susceptibility promoted by other acquired conditions including trauma, metabolic or ischemic disorders, neoplasia, etc is suggested. A wide variety of lesions, including tumors, have been reported in many studied series.(1-9)

The aim of this study is to found out tumoral lesions in surgical specimens of temporal lobectomy and hippocampus.

## **Material And Methods**

Consecutive surgical specimens of hippocampi and temporal lobes excized from patients having chronic pharmaco-resistant epilepsy were received and prospectively studied between October 1997 and December 2004. This study was done in Epilepsy center at Damascus University, Syria.

A macroscopic study was done before fixation, followed by second macroscopic study of serial cut sections of 1.5-2 mm after fixation in 4% formalin. Paraffin embedding and hematoxylin-eosin staining of 5 micron-cut sections were done. Systematic microscopic study of these HE-stained sections was performed consecutively.

## **Results**

Sixty six consecutive surgical specimens from 66 patients were received and studied. Our series included 33 males and 33 females (2-45 y; average age was 22 y). The duration of epilepsy varied between 1 to 32 years (mean was 16.2 y). Pathological findings showed some constant changes in the temporal lobe and hippocampus that were observed in all cases including disorganization of the temporal lobe cortex. Neuronal edema with vacuolization and ballooned neurons were noted. This was mostly noted in the dentate nucleus (fig 1). Cell injury and loss was resulted in disorganization and differing in density of neuron layers in the cortex. Various degrees of astrogliosis in the cortex, and various degrees of focal or diffuse astrogliosis in the white matter were noted (fig 2).

Vascular malformations were found in 5 cases (7.5%); vascular arteriovenous malformation was observed in two cases, and cavernous hemangiomas was observed in three other cases, one of them in the hippocampus.

Neuronal and glioneuronal tumors/malformations were seen in 20 cases (30%). In four cases, these lesions were in both temporal lobe and hippocampus, while in ten cases the lesion were only observed in the

hippocampus. This group included the following lesions: dysembryoplastic neuroepithelial tumors (DNETs) in 11 cases (Fig 3), gangliogliomas in 10 cases, and ganglioneuromas in six cases. These lesions were bifocal, multifocal, or associated together in the temporal lobe or hippocampus, or both.

Gliial tumors were found in 3cases (4.5% of cases) including 2 low grade fibrillary astrocytoma in the temporal lobe, and one low grade oligodendroglioma in the temporal lobe and the hippocampus.

### **Discussion**

Some tumors are known to be frequently associated with epilepsy, such as dysembryoplastic neuroepithelial tumors (DNETs), ganglioneuromas and gangliogliomas, which can be either bilateral or multifocal. (2,10-12) These tumors are believed to be of hamartomatous origin by some authors, as they are composed of mature multiple cell types.(10,13,14) Other tumors were reported in some cases of pharmaco-resistant temporal epilepsy, such as low grade astrocytomas, oligodendrogliomas, oligoastrocytomas, and vascular tumors,(15) and mixed or composite tumors.(16,17) Their incidences varies widely from one series to another. Malformations reported in epileptic series included vascular malformations,(18) white matter neuronal heterotopia,(19) lesions of tuberous sclerosis, and neuronal or glioneuronal hamartomas.(13,17,18,20) It is suggested that cortical malformations can both form epileptogenic foci and alter brain development in a manner that causes a diffuse hyperexcitability of the cortical network.(21) Glioneuronal lesions appear to be highly epileptogenic.(13)

In our series, tumors or tumor-like lesions were found in 28 cases (42%); we had 3 cases of low grade gliial tumors, 20 cases of glioneuronal tumors and hamartomas, and five vascular tumors and malformations. Most of the glioneuronal tumors were bifocal, multifocal, or associated with each other, with transitional zones or "composite tumors" as described by some other authors.(22) The juxtaposition of these tumors, and the transition between DNETs, gangliogliomas, or hamartomatous glioneuronal lesions might support the hypothesis that all these tumors are of hamartomatous origin. The relationship and the transition between these lesions have also been reported other authors.(16,23)

We have to note that all of the tumors and the malformations observed were associated with cortical disorganization, and neuronal injury and loss.

Neuronal damage and loss have been well documented in studies of epilepsy. This was evident in all of our cases, affecting especially the pyramidal cells in the cortex and the granule cells in the dentate gyrus. The loss of a critical number of interneurons in the dentate gyrus was suggested as a possible cause of seizure initiation.(24)

The histopathology of "cortical dysplasia" or "cortical dysgenesis" as described by the authors(3,7,19) includes a variety of structural changes which could be focal, multifocal, or diffuse, resulting in changes in the neuronal network inciting seizures attacks:(25) neuronal migration abnormalities, diffuse architectural disorganization of the cortex with cortical laminar disruption, gyral fusion, clusters of atypical neurons and glial cells within the cortex, malalignment of neurons, and neuronal cytomegaly. Changes of the above described "cortical dysplasia" are observed in all of our studied cases. The term "cortical dysgenesis or disorganization" might be more appropriate. Irregular brain surface and irregular cortical thickness were always noted in our cases, which might be the consequence of neuronal reorganization associated with glial cell reaction. It was reported that cortical dysgenesis might begin as an *in utero* migrational abnormality,(26) or as an acquired cortical dysplasia in response to perinatal brain damage.(1)

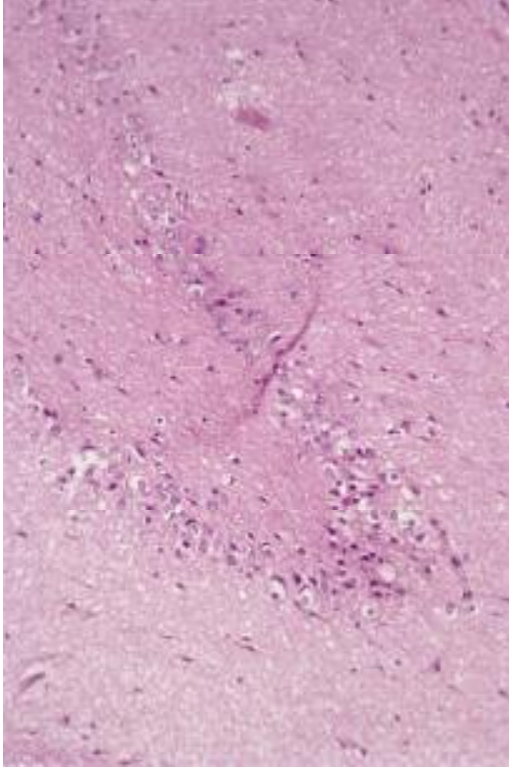
Gliosis is noted in all of the reported series of epilepsy. Astrogliosis was observed, in varying degrees, in the temporal lobe and hippocampus in all of our cases, even in patients with no remarkable abnormalities on MRI in the temporal lobe. At the same time, all of our patients had an irregular hippocampal signal on MRI. Marked subpial gliosis, with nodular densification is sometimes noted. Our two previously mentioned cases of fibrillary astrocytoma grade 1 were very difficult to distinguish from a severe gliosis. We think that progressive gliosis might be a reactive process induced by neuronal injury and loss, seizure attacks, and metabolic disorders.

### **Conclusion**

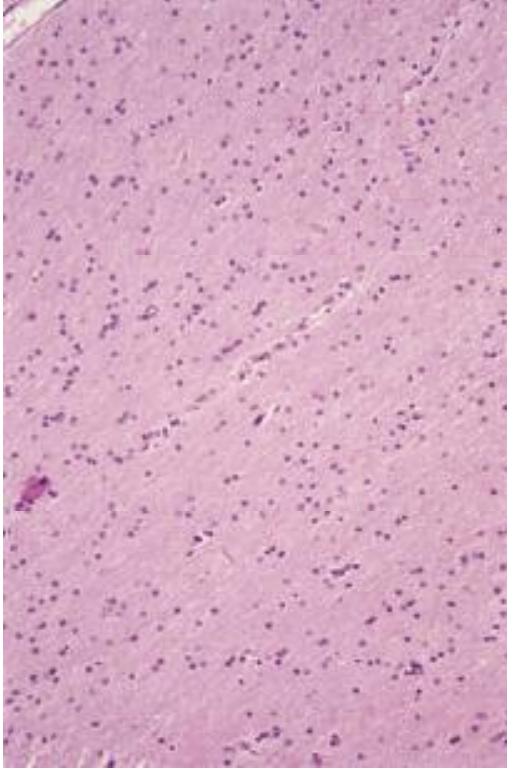
Marked modifications were noted in this histopathological study of the temporal lobe and the hippocampus in pharmacoresistant temporal epilepsy; some were constantly present, especially cortical disorganization, neuron injury and loss, and gliosis. A defined tumor or a tumor/malformation was observed in 42% of cases.

**Figures Comments:**

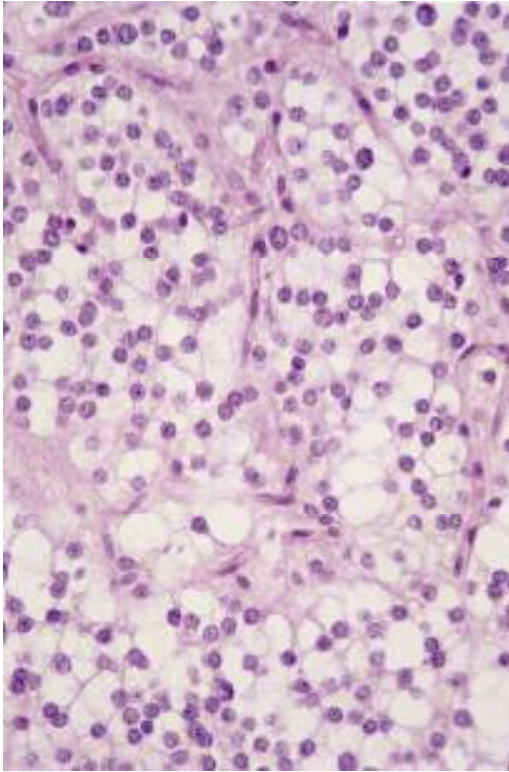
**Figure 1. Signs of cell injury in the dentate nucleus: cell edema with vacuolization and focal cell loss. (H-E stain).**



**Figure 2. Diffuse gliosis in the temporal lobe with Indian file pattern of the glial cells (H-E stain).**



**Figure 3. Dysembryoblastic neuroepithelial tumor: a common finding in epileptic cases (H-E stain).**





## References

1. Marin-Padilla M. Developmental neuropathology and impact of perinatal brain damage. III: gray matter lesions in the neocortex. *J Neuropathol Exp Neurol* 1999 May; 58(5):407-29.
2. Barbosa Coutinho LM, Hilbig A, Calcagnotto ME, ET AL. Neuropathology of hard to control epilepsy. Study of 300 consecutive cases. *Arq Neuropsiquiatr* 1999 Jun, 57,2B: 405-14.
3. Frater JL, Prayson RA, Morris III HH, Bingaman WE. Surgical pathologic findings of extratemporal-based intractable epilepsy: a study of 133 consecutive resections. *Arch Pathol Lab Med* 2000 Apr;124,4:545-9.
4. Garbelli R, Munari C, De Biasi S, ET AL. Taylor's cortical dysplasia: a confocal and ultrastructural immunohistochemical study. *Brain Pathol* 1999 Jul;9,3:445-61.
5. Li LM, Cendes F, Andermann F, et al. Surgical outcome in patients with epilepsy and dual pathology. *Brain* 1999 May;122( Pt 5):799-805.
6. Wolf HK, Zentner J, Hufnagel A, et al. Morphological findings in temporal lobe epilepsy: experience with 216 consecutive surgical specimens. *Verh Dtsch Ges Pathol*, 1994, 78:, 438-42.
7. Prayson RA, Estes ML. Cortical dysplasia: a histopathologic study of 52 cases of partial lobectomy in patients with epilepsy. *Hum Pathol* 1995 May;26,5:503-500.
8. Radhakrishnan VV, Rao MB, Radhakrishnan K, et al. Pathology of temporal lobe epilepsy: An analysis of 100 consecutive surgical specimens from patients with medically refractory epilepsy. *Neurol India* 1999 Sep;47,3:196-201.
9. Ozkara C; Ozyurt E; Hanoglu L; Eskazan E; Dervent A; Koçer N; Ozmen M; Onat F; Oz B; Kuday C. Surgical outcome of epilepsy patients evaluated with a noninvasive protocol. *Epilepsia* 2000;41(Suppl 4):S41-4.
10. Powers JM, Horopian DS. Central nervous system. In Anderson's pathology. Mosby-Year Book 10<sup>th</sup> edition. St Louis, Missouri 1996. P 2693-798.

11. Rosemberg S, Vieira GS. Dysembryoblastic neuroepithelial tumor. An epidemiological study from a single institution. *Arq Neuropsiquiatr* 1998 Jun;56(2):232-6.
12. Whittle IR, Dow GR, Lammie GA, Wardlaw J. Dsyembryoplastic neuroepithelial tumour with discrete bilateral multifocality: further evidence for a germinal origin. *Br J Neurosurg* 1999 Oct;13,5:508-11.
13. Wolf HK, Wellmer J, Muller MB, Wiestler OD, Hufnagel A, Pietsch T. Glioneuronal malformative lesions and dysembryoplastic neuroepithelial tumors in patients with chronic pharmaco-resistant epilepsies. *J Neuropathol Exp Neurol* 1995 Mar;54(2):245-54.
14. Gyure KA, Sandberg GD, Prayson RA, Morrison AL, Armstrong RC, Wong K. Dysembryoplastic neuroepithelial tumor: an immunohistochemical study with myelin oligodendrocyte glycoprotein. *Arch Pathol Lab Med* 2000 Jan;124,1:123-6.
15. Oda M, Arai N, Maehara T, Shimizu H, Kojima H, Yagishita. A Brain tumors in surgical neuropathology of intractable epilepsies, with special reference to cerebral dysplasias. *Brain Tumor Pathol* 1998;15,1:41-51.
16. Hirose T, Scheithauer BW. Mixed dysembryoplastic neuroepithelial tumor and ganglioglioma. *Acta Neuropathol Berl* 1998 Jun; 95(6):650-54.
17. Volk EE, Prayson RA. Hamartomas in the setting of chronic epilepsy: a clinicopathologic study of 13 cases. *Hum Pathol* 1997 Feb;28,2: 227-32.
18. Wolf HK, Wiestler OD. Surgical pathology of chronic epileptic seizure disorders. *Brain Pathol* 1993 Oct; 3,4:371-80.
19. Prayson RA, Reith JD, Najm IM. Mesial temporal sclerosis. A clinicopathologic study of 27 patients, including 5 with coexistent cortical dysplasia. *Arch Pathol Lab Med* 1996 Jun; 120,6:532-6.
20. Wolf HK, Birkholz T, Wellmer J, Blumcke I, Pietsch T, Wiestler OD. Neurochemical profile of glioneuronal lesions from patients with pharmaco-resistant focal epilepsies. *J Neuropathol Exp Neurol* 1995 Sep;54(5):689-97.

21. Chevassus au Louis N, Baraban SC, Gaïarsa JL, Ben Ari Y. Cortical Malformations and epilepsy: new insights from animal models. *Epilepsia* 1999 Jul;40,7:811-21.
22. Prayson RA. Composite ganglioglioma and dysembryoplastic neuroepithelial tumor. *Arch Pathol Lab Med* 1999 Mar;123,3:247-50.
23. Moreno A, de Felipe J, Garcia Sola R, Navarro A, Ramon y Cajal S. Neuronal and mixed neuronal glial tumors associated to epilepsy. A heterogeneous and related group of tumours. *Histol Histopathol* 2001 Apr;16(2):613-22.
24. Lowenstein DH. Seizures and epilepsy. In: Harisson's principles of internal medicine, 15<sup>th</sup> ed. McGraw-Hill. P 2354-69.
25. Spreafico R, Pasquier B, Minotti L, et al. Immunocytochemical investigation on dysplastic human tissue from epileptic patients. *Epilepsy Res* 1998 Sep;32(1-2):34-48.
26. Sisodiya SM. Malformations of cortical development: burdens and insights from important causes of human epilepsy. *Lancet Neurol* 2004 Jan;3(1):29-38

تاريخ ورود البحث إلى مجلة جامعة دمشق: 2008/5/8.

تاريخ قبوله للنشر: 2008/5/20.