

---

موات فورنيير

\*

---

---

الملخص

)

(

( )

%

%

%

%

---

---

\*

---

# **Fournier's Gangrene**

**Mazen Kaerallah\***

---

## **Abstract**

**We studied 23 patients diagnosed with necrotizing fasciitis of the male genitals (Fournier's Gangrene) retrospectively. We found that the disease is mainly affecting diabetic patients and patients with local trauma of the genital areas. Gram negative organisms (E. coli and Klebsiella) in addition to anaerobes were the most likely organisms isolated from the site of the lesions. The morbidity and spent before surgical intervention. The mortality rate rose from 28.5% to 55% in patients above 64 years of age and from 14.2% to 66.6% when the surgical intervention is delayed more than 48 since the beginning of the symptoms.**

---

\* Department of Surgery – Faculty of Medicine – Damascus University.

\_\_\_\_\_

---

[20, 19]  
[22] [21] ( )  
[23]  
[24]  
.[25]  
[18] .[11, 10, 9, 8, 7, 6, 5, 4, 3, 2, 1]  
.[26]  
.[27]  
.[6]  
[28]  
.[31] [30, 29]  
.[15, 14, 12]  
[13]  
[16]  
[17] HIV

-----

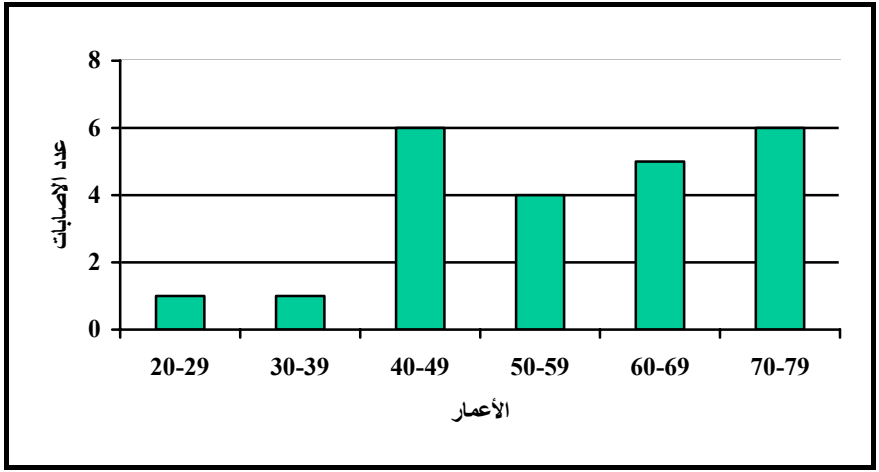
//

//

% , .

% ,

( )



% ،

( )% ،

( )% ،

( )% ،

Paraphimosis

:

% , )

(

%

% ,

%

% ,

% ,

%

%

% ,

%

% ,

% ,

% ,

% ,

%

% ,

(% , )

% ,

SIRS

---

)  
(% ) ( .  
% ,  
)  
(  
)  
(  
%  
% ,  
(P Value< )  
% )  
(% ,





---

<b>P Value</b>			
, >	%	% ,	

<b>P Value</b>			
, >	% ,	% ,	

---

## المصادر

- 1- Iorianni P, Pliver CC. Synergistic soft tissue infection of the perineum. *Dis Colon Rectum*. 1992; 35:640
- 2- Nickel JC, Morales A. Necrotizing fasciitis of the male genitalia (Fournier's gangrene). *Can Med Assoc J*. 1983; 129:445
- 3- Rea WJ, Wyrick WJ, Jr. Necrotizing fasciitis. *Ann Surg*. 1970; 172:957
- 4- Stone HH, Martin JD. Synergistic necrotizing celluliti, *Ann Surg*, 1982;175:705-711
- 5- Eke N. Colorectal cancer presenting as Fournier's gangrene. *Am J Gastroenterol* 1999 Mar;94(3):858-9
- 6- Brissiaud JC, Azam P, Paret B, Lopy J, Louis C, Collet F. Skin gangrene of the external genitalia. Report of 44 cases]. *Chirurgie* 1998 Sep;123(4):387-93
- 7- El Khader K, el Fassi J, Nouri M, Ibn Attya A, Hachimi M, Lakrissa A. Fournier's gangrene. Analysis of 32 cases. *J Urol (Paris)* 1997;103(1-2):32-4
- 8- Stephens BJ, Lathrop JC, Rice WT, Gruenberg JC. Fournier's gangrene: historic (1764-1978) versus contemporary (1979-1988) differences in etiology and clinical importance. *Am Surg* 1993 Mar;59(3):149-54
- 9- Benchekroun A, Lachkar A, Bjjou Y, Soumana A, Faik M, Marzouk M, Belahnech Z, Farih MH. Gangrene of the external genital organs. Apropos of 55 cases. *J Urol (Paris)* 1997;103(1-2):27-31
- 10- Smith GL, Bunker CB, Dinneen MD. Fournier's gangrene. *Br J Urol* 1998 Mar;81(3):347-55
- 11- Hejase MJ, Simonin JE, Bihrlle R, Coogan CL. Genital Fournier's gangrene: experience with 38 patients. *Urology* 1996 May;47(5):734-9
- 12- Langdon DE. Gamagami et al. Fournier's gangrene with obstructing cancer. *Am J Gastroenterol* 1998 Oct;93(10):1999-2000
- 13- Lederman E, Mathieu D, Lescut D, Wattel F, Paris JC. Perineal anaerobic necrotizing cellulite after preoperative radiotherapy for rectal cancer. *Gastroenterol Clin Biol* 1998 Mar;22(3):360-1

- 
- 14- Gamagami RA, Mostafavi M, Gamagami A, Lazorthes F. Fournier's gangrene: an unusual presentation for rectal carcinoma. *Am J Gastroenterol* 1998 Apr;93(4):657-8
  - 15- Gould SW, Banwell P, Glazer G. Perforated colonic carcinoma presenting as epididymo-orchitis and Fournier's gangrene. *Eur J Surg Oncol* 1997 Aug;23(4):367-8
  - 16- Martinelli G, Alessandrino EP, Bernasconi P, Caldera D, Colombo A, Malcovati Fournier's gangrene: a clinical presentation of necrotizing fasciitis after bone marrow transplantation. *Bone Marrow Transplant* 1998 Nov;22(10):1023-6
  - 17- Roca B, Cunat E, Simon E. HIV infection presenting with Fournier's gangrene. *Neth J Med* 1998 Oct;53(4):168-71
  - 18- Kohagura K, Sesoko S, Tozawa M, Iseki K, Tokuyama K, Fukiyama K. A female case of Fournier's gangrene in a patient with lupus nephritis. *Nippon Jinzo Gakkai Shi* 1998 Jul;40(5):354-8
  - 19- Faber HJ, Girbes AR, Daenen S. Fournier's gangrene as first presentation of promyelocytic leukemia. *Leuk Res* 1998 May;22(5):473-6
  - 20- Levy V, Jaffarbay J, Aouad K, Zittoun R. Fournier's gangrene during induction treatment of acute promyelocytic leukemia, a case report. *Ann Hematol* 1998 Feb;76(2):91-2
  - 21- Gaeta M, Volta S, Minutoli A, Bartiromo G, Pandolfo I. Fournier gangrene caused by a perforated retroperitoneal appendix: CT demonstration. *AJR Am J Roentgenol* 1991 Feb;156(2):341-2
  - 22- Brings HA, Matthews R, Brinkman J, Rotolo J. Crohn's disease presenting with Fournier's gangrene and enterovesical fistula. *Am Surg* 1997 May; 63(5):401-5
  - 23- Trapp JD, Mode DG. Fournier's gangrene in a patient with erectile dysfunction following use of a mechanical erection aid device. *J Urol* 1996 Feb;155(2):656
  - 24- Patel A, Ramsay JW, Whitfield HN. Fournier's gangrene of the scrotum following day case vasectomy. *J R Soc Med* 1991 Jan;84(1):49-50
  - 25- Sengoku A, Yamashita M, Umezu K. A case of Fournier's gangrene: was it triggered by prostatic massage *Hinyokika Kiyo* 1990 Sep;36(9):1097-100
  - 26- Ilva-Villasenor JA, Velazquez-Macias RF, Suarez JJ, Galvan-Montano A, Quintos-Aranda C. Fournier's gangrene in a newborn. *Bol Med Hosp Infant Mex* 1990 Jan;47(1):48-50

- 
- 27- Guiliano A, Lewis F Jr, Hadley K, et al. Bacteriology of necrotizing fasciitis. *Am J Surg.* 1977; 134:52-57
- 28- Sudarsky LA, Laschinger JC, Coppa GF, et al. Improved results from a standardized approach in treating patients with necrotizing fasciitis. *Ann Surg.* 1987;206:661
- 29- Korhonen K, Hirn M, Niinikoski J. Hyperbaric oxygen in the treatment of Fournier's gangrene. *Eur J Surg* 1998 Apr;164(4):251-5
- 30- Pizzorno R, Bonini F, Donelli A, Stubinski R, Medica M, Carmignani G. Hyperbaric oxygen therapy in the treatment of Fournier's disease in 11 male patients. *J Urol* 1997 Sep;158(3 Pt 1):837-40
- 31- Schultz ES, Diepgen TL, von den Driesch P, Hornstein OP. Systemic corticosteroids are important in the treatment of Fournier's gangrene: a case report. *Br J Dermatol* 1995 Oct;133(4):633-5