
تنظير باطن الرحم
(دراسة عملية في مشفى التوليد)

*

الملخص

/ . // //
:
% ,
.%,
%,
%,
%,
%,
% ,

*

Hysteroscopy

Jamil Taleb^{*}

Abstract

Hysteroscopy was done at the New Damascus University Maternity hospital in the period between 1/1/1998 and 30/9/1999.

The hysteroscoped cases were 90 and the indications were as follow:

(71) Cases were infertility (78.88 %); 45 of these were primary while the other 26 were secondary.

(6) Cases were lost IUD (6.66%), and the IUD was removed by hysteroscopy.

(4) Cases were recurrent spontaneous abortion (4.44%)

(3) Cases were untreatable uterine bleeding (3.33%).

(2) Cases were endometrial polyps (2.22%).

(2) Cases were Asherman's Syndrome (2.22%).

One case was primary amenorrhea and one case was leiomyoma.

^{*} Dep. of Obstetrics and Gynecology-Fac. of Medicine –Damascus University

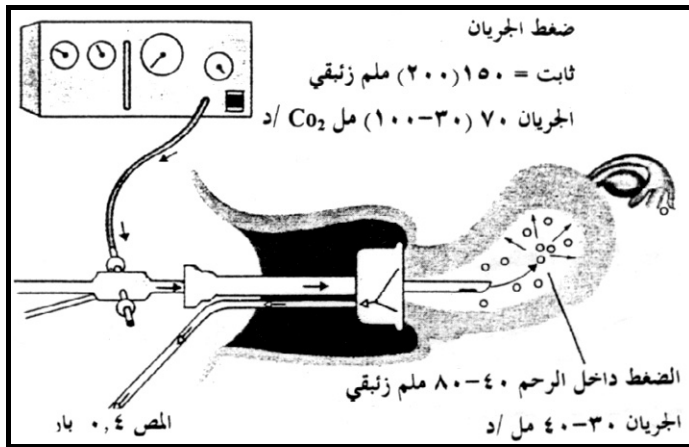
.



CO₂
[7] (%)

Pantaleoni

CO₂ -
. /



[1]

[7]

[3]

[6] % Lignocain

استطابات تنظيف باطن الرحم

أولاً: الاستطابات التشخيصية

[7] % -

-
-
%
% : -
[7]
: - ثانياً: الاستطابات العلاجية
:

[4,8]

مضادات الاستطباب

- :
- Neodym-Yag-Laser

-
- : -
-
-

المضاعفات

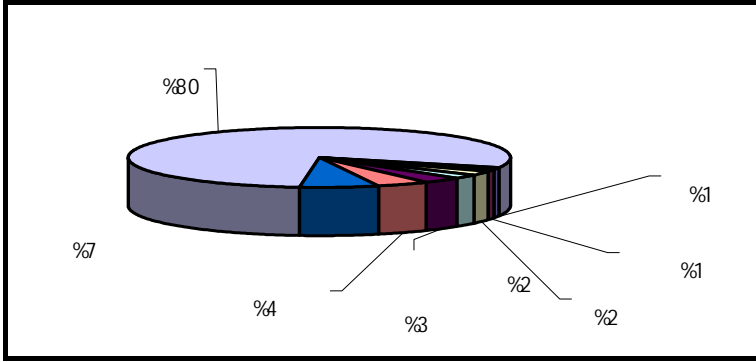
[2]

Strassman

% ,

[5,7]

. %



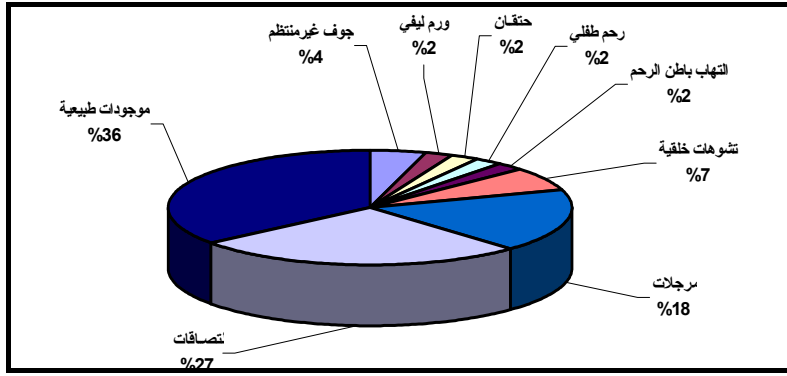
أولاً: العقم

% ,

% ,

% ,		% ,		% ,		% ,	
% ,		% ,		% ,		% ,	

% ,		% ,		% ,		% ,	
% ,		% ,					



[7].

% ,	% ,	% ,	% ,	% ,			
% ,	%	% ,					

% ,	% ,	% ,	% ,	% ,			
		% ,					

:

()

()

			1		

ثالثاً: الإسقاطات المتكررة

% ,

رابعاً: نرف معند على المعالجة

% ,

ثانياً: استخراج لولب

% ,

خامساً: متلازمة أشرمان

% ,

سادساً: استطبابات متفرقة

المضاعفات

، %

النتائج والتوصيات

المصادر

- 1- Canavan TP, Doshi NR, Endometrial cancer, Am Fam physician
1999 Jun, 59(11) 3069-77
- 2- Capella, Allonc S, Mosad F, Rougers-Bertrard C, Taylor S,
Fernandoz H. Hysteroscopic treatment of severe Asherman's
Syndrome and subsequent fertility. Hum. Rep. 1999 May 14 (5)
1230-3,
- 3- Goudas VT, Session DR. Hysteroscopic Cervical polypectomy with a
polyp snare J.Am Assoc Gynecol Laparosc 1999 May; 6(2): 195-7
- 4- 4- Grio R, Geranio R, Curti A, Piacentino, Ferraris GP Treatment of
benign uterine hemorrhage and simple endometrial hyperplasia by
endometrial ablation Minerva Ginecol. 1999 Jan.Feb S1 (49-
51).
- 5- Isaacson KB. Complications of hysteroscopy.
Obst.Gynecol.Clin.North.Am. 1999 Mar,26(1) 39-51
- 6- Lau WC, Lo Wk, Tam WH, Yuen PM. Paracervical anesthesia in
outpatient hysteroscopy : a randomized double-blind placebo-
controlled trial. Br.J.Obstet.Gynecol. 1999 Apr, 106(4): 356-9
- 7- Lindemann,H.J. Aktueller Wissentand uber die hysteroscopie
Speculum (Schering) Geburtshilfe / Frauen - Heilkunde / Strahlen –
Heilkunde 4 (1991) 3-11
- 8- 8- Romer, T. Treatments of recurrent bleeding disorder during
replacement therapy by transcervical endometrial ablation.
Gynecol.Obstet.Invest. (1999, 47 (4) 255-7)

.

